

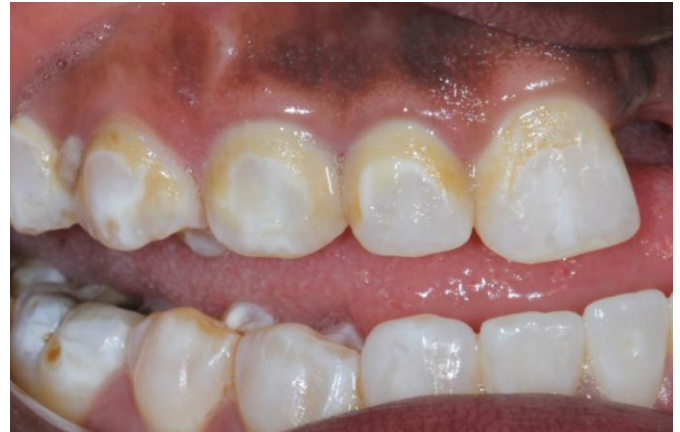September 5, 2012

CANARY CASE REPORT: DETECTING CARIES AROUND ORTHODONTIC BRACKETS

Detecting and monitoring white spots and early carious lesions around orthodontic brackets is challenging. Early detection may allow the clinician to start remineralization therapy and to motivate the patient to improve their oral hygiene. The Canary System's small beam allows clinical staff to detect and monitor the enamel status at the margins of orthodontic brackets. If caries is found early a remineralization program can be started and the lesion response monitored.

THE CANARY SCAN:

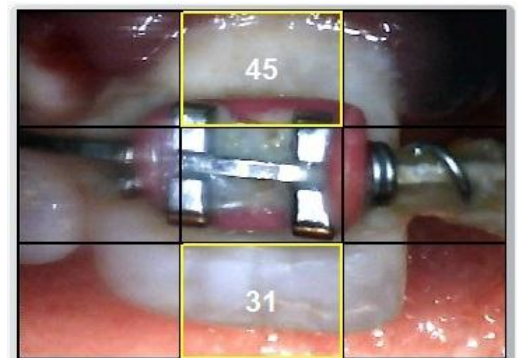

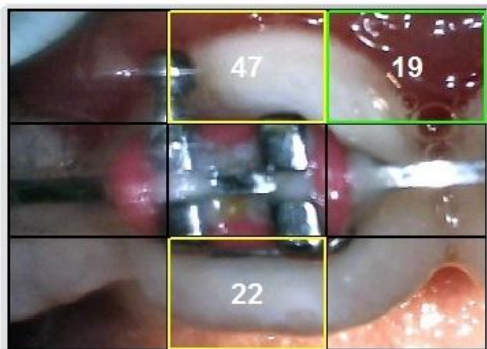
In this situation, the patient was seen in an office with brackets already in place. The oral hygiene was poor and the patient had not been back to the orthodontist for over 6 months. A Canary Scan was done on a number of teeth to examine the bracket margins. Canary Numbers were high so the patient was sent back to the orthodontist for assessment and possible removal of the brackets.



THE TREATMENT:

The orthodontist opted to remove the brackets because of the Canary readings and poor patient home care. The orthodontic brackets were removed and the presence of demineralized lesions was confirmed. The patient has been started on a remineralization regime consisting of fluoride varnish and a home base tooth paste high in calcium and fluoride. The office is continuing to monitor the results.

The Canary was able to detect caries around the margins of orthodontic brackets.



47

Tooth # 13

Tooth # 11

45